

## CASE REPORT

# TRANSCATHETER AORTIC VALVE REIMPLANTATION (TAVI) VALVE IN VALVE: CASE REPORT

DÉBORA FREIRE RIBEIRO ROCHA<sup>1</sup>, MAURÍCIO LOPES PRUDENTE<sup>1</sup>, FERNANDO HENRIQUE FERNANDES<sup>1</sup>, FÁBIO SANDOLI DE BRITO JUNIOR<sup>2,3</sup>, CLOVES GERALDINO DA SILVA JUNIOR<sup>1</sup>, GIULLIANO GARDENGHI<sup>1</sup>

## ABSTRACT

**Introduction:** The advent of transcatheter aortic valve replacement (TAVI) has changed the paradigm for managing aortic valve disease. TAVI has become specific in the last decade as a less invasive treatment alternative to the conventional surgical procedure, for inoperable, medium and high surgical risk patients. **Objective:** to report a case of a previous patient who underwent TAVI 5 years ago due to severe symptomatic aortic stenosis that evolved with degeneration of the prosthesis, progressing with implicit worsening of the functional class, undergoing TAVI valve-in-valve (ViV). **Case report:** This is a patient with multiple comorbidities who underwent TAVI in 2016 due to severe aortic stenosis. She returned to the hemodynamics service with dyspnea at rest, orthopnea, paroxysmal nocturnal dyspnea and typical precordial pain. Echocardiogram of aortic prosthesis dysfunction with severe stenosis. So, it was decided to perform TAVI ViV to treat an elderly patient with severe organic fragility and high surgical risk. Intraoperatively, a reduction in transvalvular gradients was evidenced. Postoperatively, the patient evolved with significant improvement in her previous symptoms and was discharged after 3 days for outpatient follow-up. **Conclusion:** The ViV procedure is a safe and less invasive alternative for the treatment of dysfunctional bioprostheses. The current literature reports low morbidity and mortality rates of patients related to ViV improvement and survival.

**KEYWORDS:** TRANSCATHETER AORTIC VALVE REPLACEMENT, AORTIC VALVE STENOSIS, HEMODYNAMICS.

## INTRODUCTION

Degenerative calcific aortic stenosis (AS) is more common in the elderly population, with a predominance of males. It is present in 29% of individuals over 65 years of age<sup>1</sup>.

According to the ESC (European Society of Cardiology) and the ACC (American College of Cardiology) guidelines, surgical aortic valve replacement (SAVR) was the standard treatment for symptomatic AS until 2017. However, after publication of the CoreValve High Risk trial and other randomized studies, it is recommended that the decision and choice of treatment for AS should be based on a multidisciplinary discussion involving the Heart Team. Currently, it is recommended for symptomatic patients with severe AS and age over 80 years or for younger patients with life expectancy < 10 years and no anatomic contraindications to transcatheter aortic valve implantation (TAVI), this is recommended in preference to Conventional Aortic Valve Replacement surgery (SAVR) for patients at high surgical risk (Degree of Recommendation I, Level of Evidence A) or intermediate (Degree of Recommendation IIa, Level of Evidence B)<sup>2</sup>.

In this context, the TAVI method was developed in 2002 by Alan Cribier, a minimally invasive procedure, as an effective and safe alternative in the surgical treatment of patients with severe symptomatic AS and with restrictions to

the procedure by SAVR (contraindication to surgical aortic valve replacement due to high risk surgery or technical conditions that make the surgery unfeasible, such as porcelain aorta, previous thoracic radiation, and others)<sup>3,4</sup>.

TAVI-in-TAVI was initially used in the acute management of suboptimal bioprosthesis function during a TAVI procedure. However, with the technological advances of the devices and the initial experience of TAVI-in-TAVI, there was an expansion of the potential indications and use for the correction of degenerated prostheses<sup>5</sup>.

The present report aims to describe the performance of a case of TAVI-in-TAVI five years after the original implant. Approval was obtained from the Research Ethics Committee of Hospital de Urgências de Goiânia, under CAAE: 85497418.2.0000.0033.

## CASE REPORT

A 77-year-old female patient with multiple comorbidities was admitted to the hemodynamics service in April 2021 for TAVI ViV. It is important to mention that in 2016 this patient underwent TAVI due to severe AS with implantation of the Edwards XT® 23 mm prosthesis.

She recently evolved with dyspnea at rest, orthopnea, and paroxysmal nocturnal dyspnea associated with typical chest pain on minimal exertion.

1. Hospital ENCORE, Aparecida de Goiânia
2. Hospital Sírio Libanês, São Paulo/SP
3. Instituto do Coração do Hospital das Clínicas da Faculdade de Medicina da Universidade de São Paulo (InCor-HC/FMUSP) - São Paulo/SP



## ADDRESS

GIULLIANO GARDENGHI  
Hospital ENCORE  
Rua Gurupi, Qd.25, Lt.06/08 - Setor Vila Brasília  
Aparecida de Goiânia GO - CEP: 74905-350  
E-mail: ggardenghi@encore.com.br

Transthoracic echocardiogram (TTE) performed on 12/23/2020 showed severe AS (peak gradient of 51 mmHg, mean gradient of 28 mmHg, peak velocity of 4.5 m/s and valve area of 1.0 cm<sup>2</sup>), aortic insufficiency, high probability of PAH (PASP 75 mmHg), preserved left ventricular (LV) systolic function (LVEF 66%) and significant LV diastolic dysfunction.

In view of these circumstances, we chose to perform ViV because she was a symptomatic patient (stage D1), an elderly woman with marked organic fragility and high surgical risk (STS score, mortality 4.4 and morbidity 22%), but with life expectancy longer than one year regardless of the AS.

Preoperatively, the patient underwent cardiac catheterization with manometry that revealed the presence of a pressure gradient between the left ventricle and the aorta; divergent pressure in aorta; prosthesis in incompetent aortic position with double lesion (important insufficiency and stenosis); predominance of stenosis with a transprosthetic gradient of 50 mmHg and coronary circulation with mild obstructive lesions (Figures 1A and 1B).

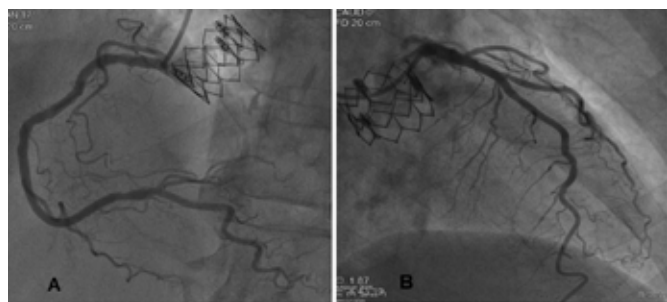


Figure 1: Coronary angiography of 02/25/2021 showing right (A) and left coronary circulation (B) with mild obstructive lesions.

In view of this situation, on 04/12/2021, the Sapien® 23 mm prosthesis was implanted without clinical or angiographic complications (Figures 2A and 2B), whose post-procedure manometry showed a significant reduction in the pressure gradient between LV and aorta from 38 mmHg to 8 mmHg.

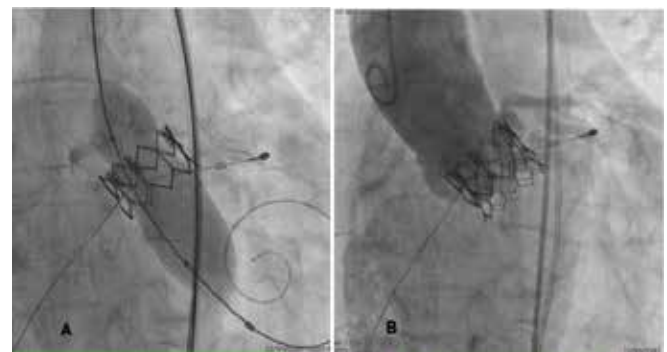


Figura 2: Implante de prótese Evolut R® 23 mm - A: pré-intervenção e B: pós-intervenção

On 04/13/2021, she underwent postoperative control TT ECHO, which showed aortic biological prosthesis with good mobility of the leaflets, with peak left ventricle-aorta (LV-Ao) gradients of 33 mmHg and mean of 18 mmHg; moderate dilatation of the left atrium (indexed LAV of 38ml/m<sup>2</sup>) (Figures 3A and 3B).

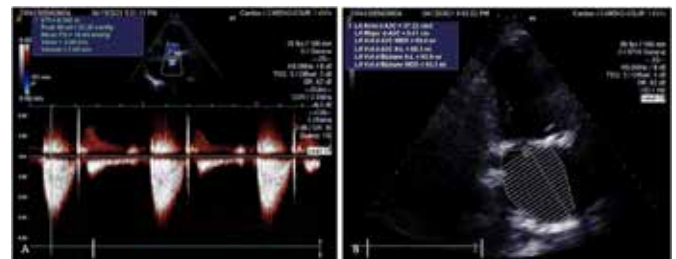


Figure 3: Doppler echocardiogram tracings. A - Doppler evidencing left ventricle (LV) - Aortic (Ao) gradients. B - Doppler demonstrating moderate dilatation of the left atrium (LA)

With good clinical evolution and significant improvement in previous symptoms, the patient was discharged on 04/17/2021 for outpatient follow-up.

### DISCUSSION

With the increase in survival of this population treated with TAVI, a progressive increase in a portion of patients who develop implanted valve dysfunction is observed 6,7. Thus, ViV for replacement of degenerated surgical aortic bioprostheses is a very interesting technique due to the high risk associated with surgical valve replacement in elderly patients 5.

In several meta-analyses published between 2018 and 2021 comparing ViV with Redo-SAVR, there was no significant difference in perioperative or late mortality between the groups, with lower rates of permanent pacemaker implantation, shorter hospital stay in the ViV group 8-10.

In the Global Valve-in-Valve Registry including 202 patients with degenerated bioprostheses, there were no significant differences in mortality between two types of prostheses (CoreValve and Edwards-SAPIEN), major vascular complication or stroke at 30 days and 1-year survival. The implantation of Edwards-SAPIEN models, however, was an independent predictor for high post-procedural gradients (p: 0.02)<sup>11</sup>.

Takagi et al<sup>9</sup> emphasize in their study that in patients with degenerated aortic valve bioprostheses, especially elderly or high-risk patients, VIV-TAVI may be a safe and viable alternative to Redo-SAVR. They cite, and the authors of the present case report agree with this statement, that the publications so far involve only observational studies with important differences in the baseline characteristics of the patients studied, making it necessary to carry out randomized clinical trials to elucidate this knowledge gap.

## CONCLUSION

The ViV procedure is a new, promising, safe and less invasive alternative for the treatment of dysfunctional bioprostheses that has shown low morbidity and mortality rates, being a possibility that may change the indication of prosthesis selection in the initial procedure, favoring biological prostheses. Therefore, we emphasize the need for randomized studies to determine the efficacy and safety of the ViV procedure in patients with aortic prosthetic valve dysfunction.

## REFERENCES

1. Siqueira ARO, Siqueira SRO, Mangione JA, Cristovão SAB, Mauro MFZ, Costalnt FAA. TAVI: the Game Changer for the Future! Are We Ready to Implant Hope into Patient's Heart? *Int J Cardiovasc Sci.* 2015;28(5):347-356.
2. Baumbach A, Dudek D, BaumgartnerH, Windecker S, Haude M. Evolving paradigms in valvular heart disease: where should guidelines move? *EuroIntervention.* 2019;15(10):851-856.
3. Follador W, Mendoza CF, Gonçalves J, Sartori L, Ferreira CN. Estenose valvular aórtica e o uso de TAVI: revisão narrativa das evidências publicadas e avaliação básica de custos. *J Bras Econ Saúde.* 2018;10(1):36-44.
4. Mangione FM, Mauro MFZ, Cristóvão SAB, Dutra GA, Mangione JA. Principais estudos clínicos sobre implante de válvula aórtica transcater. *Rev Soc Cardiol Estado de São Paulo.* 2017;27(1):20-5.
5. Vrachatis DA, Vavuranakis M, Tsoukala S, Giotaki S, Papaioannou TG, Siasos G, Deftereos G, Giannopoulos G, Raisakis K, Tousoulis D, Deftereos S, Vavuranakis M. TAVI: Valve in valve. A new field for structuralists? Literature review. *Hellenic Journal of Cardiology.* 2020; 61(3):148-153.
6. Gaia DF, Couto A, Breda JR, Ferreira CBND, Macedo MT, Gimenes MV, Buffolo E, Palma JH. Implante valve-in-valve transcater em posição aórtica: uma mudança de seleção? *Braz. J. Cardiovasc. Surg.* 2012;27(3):355-361.
7. Nalluri N, Atti V, Munir AB, Karam B, Patel NJ, Kumar V, Vemula P, Edla S, Asti Deepak, Paturu A, Gayam S, Spagnola J, Barsoum E, Maniatis GA, Tamburrino F, Kandov R, Lafferty J, Kliger C. Valve in valve transcatheter aortic valve implantation (ViV-TAVI) versus redo—Surgical aortic valve replacement (redo-SAVR): A systematic review and meta-analysis. *Journal of Interventional Cardiology.* 2018;31(5):661-671.
8. Tam DY, Vo TX, Wijesundera HC, Dvir D, Friedrich JO, Fremes SE. Transcatheter valve-in-valve versus redo surgical aortic valve replacement for the treatment of degenerated bioprosthetic aortic valve: A systematic review and meta-analysis. *Catheter Cardiovasc Interv.* 2018;92(7):1404-1411.
9. Takagi H, Mitta S, Ando T. Meta-analysis of Valve-in-Valve Transcatheter versus Redo Surgical Aortic Valve Replacement. *Thorac Cardiovasc Surg.* 2019;67(4):243-250.
10. Al-Abcha A, Saleh Y, Boumegouas M, Prasad R, Herzallah K, Baloch ZQ, Abdelkarim O, Rayamajhi S, Abela GS. Meta-Analysis of Valve-in-Valve Transcatheter Aortic Valve Implantation Versus Redo-surgical Aortic Valve Replacement in Failed Bioprosthetic Aortic Valve. *Am J Cardiol.* 2021;146:74-81.
11. Dvir D, Webb J, Brecker S, et al. Transcatheter aortic valve replacement for degenerative bioprosthetic surgical valves: results from the Global Valve-in-Valve Registry. *Circulation* 2012;126(19):2335–2344